Vaginal Examination during Labor

Goal:

To equip students with the knowledge, clinical skills, and professional attitude necessary to perform a vaginal examination safely, accurately, and respectfully in obstetric and gynecologic settings.

Specific Learning Objectives:

By the end of the session, students should be able to:

1. Define vaginal examination and its indications in obstetric and gynecological practice.
2. Describe the normal female pelvic anatomy relevant to the examination.
3. Identify the key components assessed during a vaginal examination (e.g., cervical dilation, effacement, station, presenting part, membrane status).
4. Perform a vaginal examination using a model or simulator.
5. Accurately interpret and document examination findings.

Outlines:

- ☞ Introduction
- ☞ Definition
- ☞ Indication.
- ☞ Contraindication.
- ☞ Special consideration before VE:

- ☞ Guidelines for VE during labor
- ☞ Information Gained from VE
- ☞ Equipment
- ☞ Technique for Performing VE
- ☞ Performance Checklist
- ☞ References

Introduction:

Vaginal examination is a critical clinical skill used in obstetrics and gynecology to assess cervical changes, fetal position, and progress of labor. It provides essential information for decision-making during labor and delivery. Performed with care and respect for patient privacy, the procedure requires a thorough understanding of pelvic anatomy, sterile technique, and effective communication to ensure both accuracy and patient comfort.

Definition:

Vaginal examination (VE) is performed by the nurse or physician. It is considered a "blind examination" because the assessments are made by feeling not seeing the cervix.

Deference between PV&VE

1. PV = Per Vaginal:

- ☞ Refers to the route of examination or intervention.
  - ➔ Meaning Literally "through the vagina."
  - ➔ Example:
  - ☞ PV bleeding → vaginal bleeding.
  - ☞ PV examination → any exam performed via the vaginal

route (digital, speculum, etc.).

Scope: Can mean a *digital examination, a speculum examination, or even drug administration (e.g., PV misoprostol).

It does not inherently specify what was assessed.

2. VE = Vaginal Examination

➔ Meaning: Specifically the digital examination to assess labor progress, cervical changes, fetal position, station, etc.

Usage: A type of PV examination but much more specific in obstetrics.

➔ Example:

VE findings: "3 cm dilated, 50% effaced, vertex at –2 stations."

Scope: Always manual (gloved fingers), performed to assess the cervix, membranes, and presenting part.

- ☞ PV → route (per vaginal), general term.
- ☞ VE→ specific type of PV exam used in labor to assess progress.

All VEs are PVs, but not all PVs are VEs.

Indications:-

1-Confirm the onset of labor.

2-Determine the condition & dilatation of the cervix.

3-Determine the station & position of the presenting part.

4-Identify the relationship of the fetus to the pelvis.

5-Early diagnosis of an abnormal presentation.

6-Identify complications as (cord prolapse, placenta previa).

7- Perform an artificial rupture of membrane of membrane.

8- Apply a fetal scalp electrode.

Contraindications: -

1- Placenta previa.
2- Premature labors (the initial VE should be undertaken by the obstetrician).

Special consideration before VE:

1- In early labor, perform the VE between contractions, focusing primarily on the extent of cervical dilatation and effacement.
2- At the end of the 1st stage perform the examination during a contraction, when the uterine muscle pushes the fetus downward. This examination will focus on assessing fetal descent.
3- If the amniotic membrane ruptures during the examination, record the F.H.R. Then note the time, and describe the color, odor, and approximately amount of fluid.
4- After the membranes rupture, perform the VE only when labor changes significantly to minimize the risk of introducing intrauterine infection.

Information gained from doing an examination per vagina: -

1-External genitalia:-

Any abnormalities, such as varicosities, edema, warts or signs of infection should be noted. Scarring of previous perineal or labial trauma or female genital mutilation should be noted.

The color, consistency, amount, and odor of any discharge or bleeding from the vagina should be recorded; amniotic fluid

may be seen if the membranes have ruptured.

2-Vagina:-

The vagina should feel warm and moist, with soft distensible walls. A hot, dry vagina could be indicative of dehydration, infection or obstructed labor. The feels tense may be associated with fear or previous scarring. The presence off varicosities, a cystocele should be noted. A full rectum may be felt through the posterior vaginal wall.

3-Cervix:-

The cervix is assessed for position, consistency, effacement, dilatation, and application to the presenting part.

4-Effacement:-

Effacement is known as; "taking up", shortening and thinning of the cervix.

- During the first stage of labor, the cervix shortens in length from 2cm to being almost paper-thin.
- This process starts before dilation in primi-gravida and occurs after dilatation in multipara.
- The degree of effacement is documented in a percentage, with 0% being a long, thick cervix and 100% being paper-thin.

5-Dilatation: -

Cervical dilatation refers: to the opening or widening of the cervix. It is measured in centimeters, ranging from closed to being 10 cm or completely dilated.

6-Position of the cervix:-

If the woman in true labor, the cervix is usually but not always anterior and can be easily found during a VE at the top of the vaginal canal.

-Often in a pre-term labor, false labor and sometimes in early labor, the cervix is posterior, causing the examiner to reach further in to find the cervix.

7-Molding: is an important indication of how adequately the pelvis can accommodate the fetal head.

8-Station:

Station refers to the relationship of the level of the presenting part with the ischial spine of the mother.

- The birth canal is divided into fifth above and below the ischial spines.
- If the lowest portion of the presenting part is below the ischial spines, the station is a positive status.
- The station can range from -5 to +5.
  - If the head is 2 cm above the ischial spines, the station is –2
  - If the lowest portion of the presenting part (e.g. the fetal head) is at the level of the ischial spines, the head is said to be at "0 station".
  - If the head is 1 cm below the ischial spines, the station is + 1.

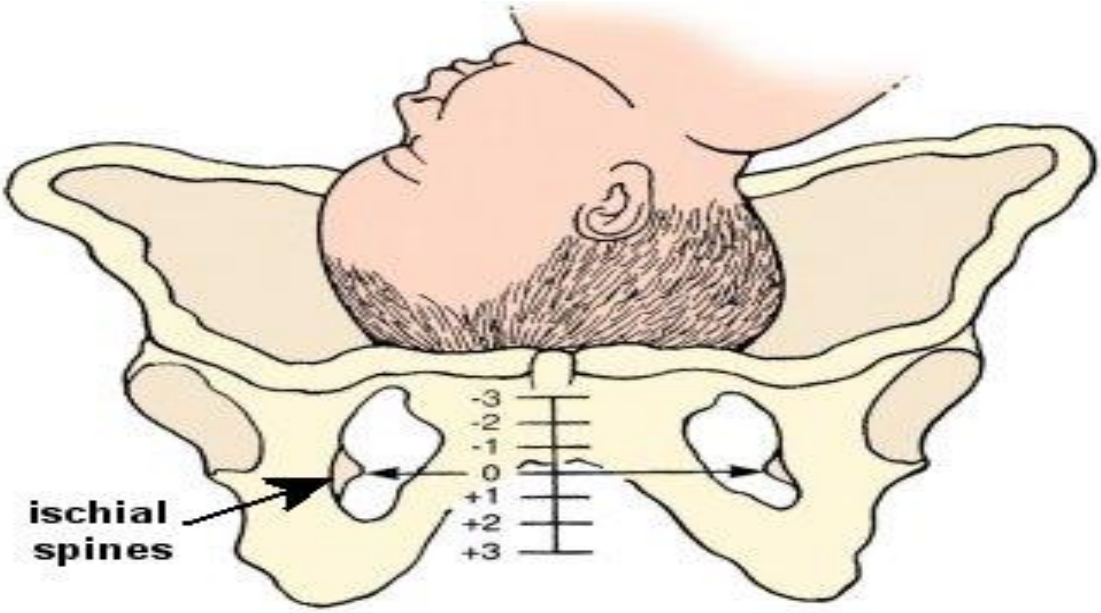

https://www.google.com/search?q=+station+vaginal+examination&client=firefox-b-

9-Presentation: -

The presenting part is referred: to the part of the fetus that appears first at the cervical os.

- Upon entering a dilated cervix, the examiner should palpate the presenting part to determine if the position of the fetus is vertex, breech, or some other presentation (e.g. face, brew, shoulder or arm).
- Upon palpating the presenting part the examiner should gently push to determine if the presenting part is well engaged or if it is ballotable (i.e. floats away from the examiner's fingers upon palpation).

-This an important assessment when the amniotic sac is ruptured; if the fetus ballotable and the amniotic sac is ruptured the chances for prolapsed cord increase with ambulating.

- A cervix with well engaged the presenting part is associated

with good uterine activity.

10- Position:-

Fetal position describes the relationship of the presenting part to the maternal pelvis.

Three terms are used to describe **the position.**

1. Left or right: refers to the maternal side that the part is facing.
2. Part of the fetus: refers to as the denominator or reference point" if the fetus is:
   - ☞ Vertex, the occiput is the denominator, or the term used to describe the position.
   - ☞ Sacrum is used for breech presentation.
   - ☞ Mentum is used for face presentation.
   - ☞ Scapula is used for shoulder and arm presentation.

3. Anterior, posterior, or transverse describes which said of the maternal pelvis the part is facing.

- Left occiput anterior (LOA) means that the fetal occiput is against the left anterior portion of the maternal pelvis.
- Right occiput transverse (ROT) means that the fetal occiput is against the right side of the maternal pelvis.
- Occipito-posterior (OP) position when the occiput is against the mother's spine.

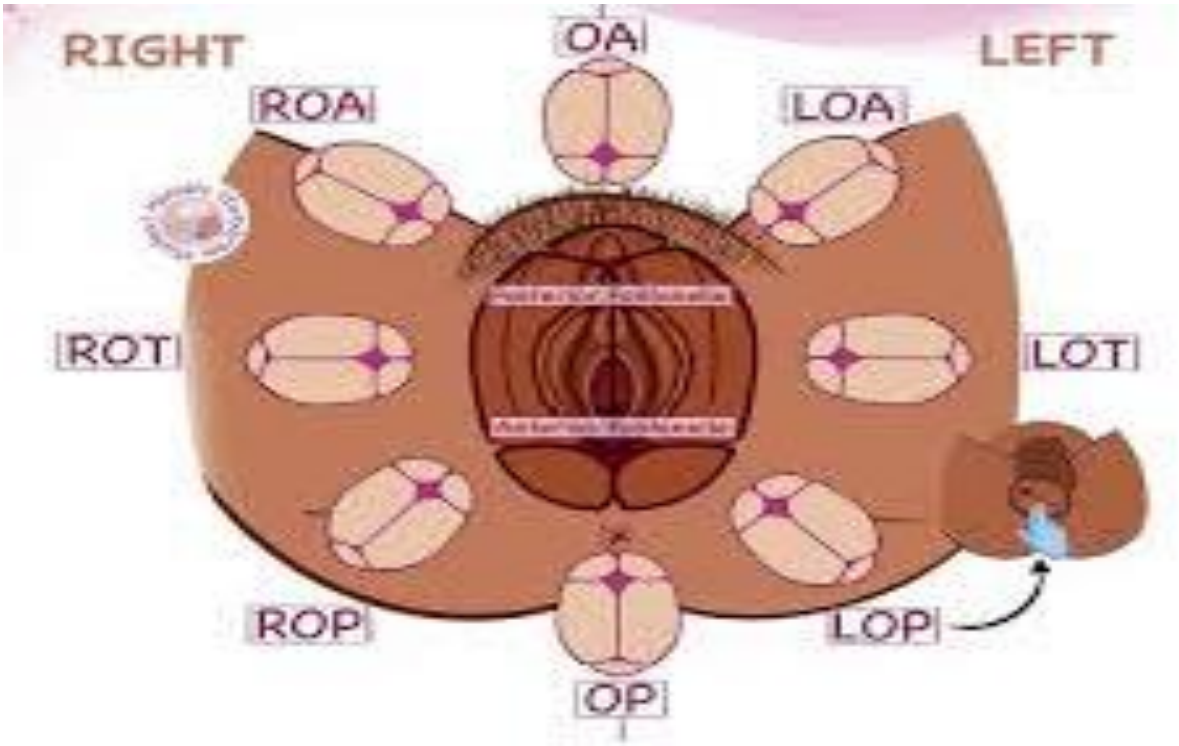

https://www.google.com/search?q=position+vaginal+examination&client=firefox-b-

11- Status of amniotic membranes and fluid: -

- ☞ Intact membranes may be felt as a shiny surface over the presenting part.
- ☞ This can be difficult particularly in early labor or if the fore-waters are shallow and the membranes tightly pressed against the presenting part.

Vaginal Examination (During Labor)

Nursing action	Rational
1. Introduce yourself and explain procedure to the woman.	☞ Obtain verbal consent to reduce anxiety and promote co-operation.
2. Instruct woman to empty her bladder before beginning examination.	☞ Promotes comfort and accuracy of evaluation.
3. Provide privacy.	☞ Shows respect & feelings of self-value.
4. Assist the woman to assume the proper position (Lithotomy, dorsal recumbent position or lateral position). Put a rolled towel under the right hip if the woman.	☞ To promote accuracy of evaluation. ☞ To avoid aorto-caval occlusion and supine hypotension.
5. Place a drape over the woman in diamond shape with one corner at her sternum, one corner over each of knee, and one corner over her perineum.	☞ To expose the woman's perineal area while covering the rest of her body.
6. Placing the rubber sheet beneath the woman buttocks	☞ To save the bed linen.
7. Remove any sanitary towels or under wear.	
8. Undertake an abdominal palpation.	☞ to ascertain the lie, presentation, position, degree of

	engagement and auscultate the fetal heart
9. Wash hands and done gloves	
10. Expose the area for examination	
11. Inspect the vulva & perineum for Edema or congestion in the labia. 12. Warts or sores and a previous tear or episiotomy. 13. Discharge or bleeding from the vaginal orifice.	
14. Swab the perineum from front to back using cotton ball or gauze soaked in antiseptic solution, use each swab once and dispose it.	☞ This help prevention of ascending infection during examination
15. Lubricate the first two fingers of the examining hand. (If the membrane is ruptured use antiseptic solution). 16. If using nitrazine paper do not use the lubricant until after the nitrazine test is complete.	☞ To facilitate the insertion.
17. Ask the mother to relax her pelvic muscles by taking several deep breaths & slowly releasing the air as the examiner performs the internal examination.	☞ Makes the examination less uncomfortable (if the woman is anxious, she may tense her abdomen, pelvic and thigh muscles closing her thigh, this

	makes vaginal examination difficult.
18. From standing position using thumb & forefinger of non-dominant hand to spread the labia.	☞ - To widen the area and facilitate insertion of the index & middle.
19. Wait until the woman is in between contractions before inserting finger. 20. Gently insert the two lubricated fingers (index and middle fingers of the right hand) and introduces there one above the other into the longitudinal slit of the introitus in downwards and backwards direction. 21. Keep un-inserted fingers flexed to avoid touching the woman's clitoris or anus 22. Then inspect the vaginal walls.	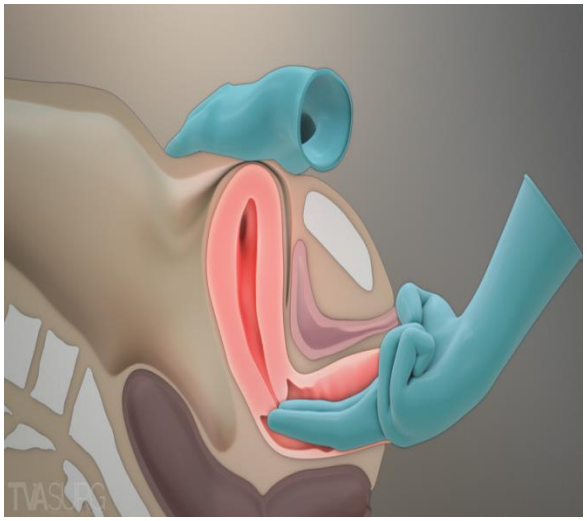 https://pie.med.utoronto.ca/TVASurg/wp-content/uploads/2022/01/casePage.png ☞ The vagina should feel warm and moist, the wall are soft & distensible.
23. Palpate the cervix to locate its position. 24. Once find the cervix turn fingers up and feel for its length and thickness. 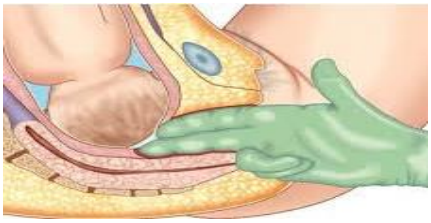	☞ Keep in mind that it may assume a posterior position in early labor and be difficult to locate it. ☞ To assess cervical effacement.

25. Move fingers slightly higher (upward) to locate the internal cervical os, 26. Rotate and spread fingers to estimate dilatation.	
27. Use non-dominant hand to gently but firmly press on the uterus.	☞ To steady the fetal presenting part against the cervix for examination.
28. Feel the presenting part of the fetus. 29. Gently push on it to determine if it is ballotable. 30. Feel for the ischial spines in the woman's pelvis.	☞ To determine the presenting part and its position and engagement. ☞ To assess the station of presenting part.
31. Check the amniotic membrane status.	
32. After obtaining the require information withdraw the fingers from the vagina.	☞ Inspect fingers for the amniotic fluid characteristics
33. Washing the vulva with antiseptic solution & put on clean pad after care.	☞ Promote comforts &prevents infection.
34. Explain the finding to the woman.	☞ To reassure the mother.
35. Return the equipment and remove the gloves	☞ Keep places clean & prevent spread of infection.
36. Wash hands	☞ Provide cleanliness.
37. Record & report the information.	

Link for vaginal examination:

https://www.youtube.com/watch?v=RwkKXCCA_0k

Vaginal Examination Checklist

Action	First Trial		Second Trial	
	Done	Note Done	Done	Note Done
1- Introduce yourself and explain procedure to the woman.				
2- Instruct woman to empty her bladder before beginning examination.				
3- Provide privacy.				
4- Assist the woman to assume the proper position. Put a rolled towel under the right hip.				
5- Place a drape over the woman in diamond shape.				
6- Placing the rubber sheet beneath the woman buttocks				
7- Remove any sanitary towels or under wear.				
8- Undertake an abdominal palpation.				
9-Wash hands and done gloves				
10- Expose the area for examination and drape the rest of body.				

11- Inspect the vulva & perineum for edema, warts, previous scare and vaginal discharge.				
12- Swab the perineum from front to back using cotton ball or gauze with antiseptic solution, use each swab once and dispose of it.				
13- Lubricate the first two fingers of the examining hand.				
14- Ask the mother to relax her pelvic muscles by taking several deep breaths & slowly releasing the air during the examination.				
15 - Using thumb & forefinger of non-dominant hand to spread the labia.				
16- Wait until the woman is in between contractions. -Gently insert the two lubricated fingers (index and middle) longitudinal, in downwards and backwards direction, then palpate the vaginal walls. - Keep un-inserted fingers flexed to avoid touching the woman's				

clitoris.				
17- Palpate the cervix to locate its position. Once find the cervix turn fingers up and feel for its length and thickness.				
18- Move fingers slightly higher to locate the internal cervical os, Spread fingers to estimate dilatation.				
19- Use non-dominant hand to gently but firmly press on the uterus.				
20- Feel the presenting part of the fetus. Gently push on it to determine if it is ballotable. Feel for the ischial spines in the woman's pelvis.				
21- Check the amniotic membrane status.				
22-After obtaining the required information withdraw the fingers from the vagina.				
23-Washing the vulva with antiseptic solution & put on a clean pad.				

24-Explain the finding to the woman.				
25- Return the equipment and remove the gloves.				
26- Wash hands				
27- Record & report the information.				
Procedure score				
Date				

Student Name: **Instructor Name:**